

Masterclass

# Management of peripheral neuropathic pain: Integrating neurobiology, neurodynamics, and clinical evidence

Robert J. Nee <sup>a,\*</sup>, David Butler <sup>b</sup>

<sup>a</sup> School of Physical Therapy, Pacific University, Forest Grove, OR 97116, USA

<sup>b</sup> Neuro Orthopedic Institute, Adelaide City West, SA, Australia

Received 2 September 2005; received in revised form 29 September 2005; accepted 3 October 2005

## Abstract

Peripheral neuropathic pain is the term used to describe situations where nerve roots or peripheral nerve trunks have been injured by mechanical and/or chemical stimuli that exceeded the physical capabilities of the nervous system. Clinical manifestations of peripheral neuropathic pain are often discussed in terms of positive and negative symptoms. Positive symptoms reflect an abnormal level of excitability in the nervous system and include pain, paresthesia, dysesthesia, and spasm. Negative symptoms indicate reduced impulse conduction in the neural tissues and include hypoesthesia or anesthesia and weakness. It is proposed that conservative management incorporating neurodynamic and neurobiology education, nonneural tissue interventions, and neurodynamic mobilization techniques can be effective in addressing musculoskeletal presentations of peripheral neuropathic pain. While a small amount of clinical evidence lends some support to this proposal, much more clinical research is necessary to identify those patients with peripheral neuropathic pain that will respond most favorably to neurodynamic mobilization techniques and clarify specific treatment parameters that will be most effective. Regardless of the results of this future research, conservative care will always need to be based on sound clinical reasoning so that interventions can be individualized to address the nuances of each patient's presentation of peripheral neuropathic pain.

© 2005 Elsevier Ltd. All rights reserved.

*Keywords:* Peripheral neuropathic pain; Neurobiology; Neurodynamics

## 1. Introduction

Neural tissues are well equipped to tolerate mechanical forces generated during the positions or movements associated with daily and sport activities (Butler, 1991, 2000; Sunderland, 1990, 1991). Peripheral neuropathic pain is the term used to describe situations where nerve roots or peripheral nerve trunks have been injured by mechanical and/or chemical stimuli that exceeded the physical capabilities of the nervous system (Butler, 2000; Gifford & Butler, 1997; Merskey & Bogduk, 1994). In addition to well recognized radiculopathies and nerve entrapments, peripheral neuropathic mechanisms may have a role in some presentations of other musculoskeletal syndromes commonly seen in sport, such as lateral epicondylalgia (Izzi, Dennison, Noerdlinger,

Dasilva, & Akelman, 2001; Yaxley & Jull, 1993), achilles tendinosis (Hirose & McGarvey, 2004; McCrory, Bell, & Bradshaw, 2002), heel pain (Meyer, Kulig, & Landel, 2002; Schon, Glennon, & Baxter, 1993; Shacklock, 1995a), and inversion ankle sprains (Pahor & Toppenberg, 1996). The goal of this masterclass paper is to review the neurobiological mechanisms associated with musculoskeletal presentations of peripheral neuropathic pain and offer management ideas that integrate neurobiology, neurodynamics, and clinical evidence.

## 2. Clinical presentation

### 2.1. Symptomatic complaints

Clinical manifestations of peripheral neuropathic pain are often discussed in terms of positive and negative symptoms. Positive symptoms reflect an abnormal level of excitability in the nervous system and include pain, paresthesia, dysesthesia, and spasm. Negative symptoms

\* Corresponding author. Tel.: +1 503 352 3161; fax: +1 503 352 2995.  
E-mail address: [neerj@pacificu.edu](mailto:neerj@pacificu.edu) (R.J. Nee).

indicate reduced impulse conduction in the neural tissues and include hypoesthesia or anesthesia and weakness (Baron, 2000; Devor & Seltzer, 1999; Hall & Elvey, 1999; Harden, 2005; Woolf, 2004; Woolf & Mannion, 1999).

Painful sensations associated with peripheral nerve injury involve some combination of nerve trunk pain and dysesthetic pain (Asbury & Fields, 1984). Nerve trunk pain is typically described as a deep and aching sensation that has been attributed to increased activity from mechanically or chemically sensitized nociceptors in the connective tissue sheaths of the nervous system (i.e. *nervi nervorum* and *sinu-vertebral* nerves) (Asbury & Fields, 1984; Bove & Light, 1997; Edgar & Nundy, 1966; Hromada, 1963; Kallakuri, Cavanaugh, & Blagoev, 1998). Dysesthetic pain is often characterized as an unfamiliar or abnormal sensation such as burning, tingling, electric, searing, drawing, or crawling (Asbury & Fields, 1984), and it is thought to be the result of volleys of impulses originating from damaged or regenerating afferent fibers that have become hyperexcitable (i.e. abnormal impulse generating sites) (Asbury & Fields, 1984; Baron, 2000; Devor & Seltzer, 1999; Woolf, 2004; Woolf & Mannion, 1999).

Nerve trunk pain and dysesthetic pain may be stimulus-evoked, meaning that they are experienced as exaggerated responses to mechanical, chemical, or thermal stimuli (Asbury & Fields, 1984; Baron, 2000; Devor & Seltzer, 1999; Hall & Elvey, 1999; Harden, 2005; Woolf & Mannion, 1999). Hyperalgesia describes an exaggerated pain response produced by a normally painful stimulus, and allodynia characterizes a pain response created by a stimulus that would not usually be painful (Merskey & Bogduk, 1994). Movements or positions that expose sensitized neural tissues to compressive, friction, tensile, or vibration stimuli can be symptomatic for patients experiencing a musculoskeletal presentation of peripheral neuropathic pain, and these phenomena would be described as mechanical hyperalgesia/allodynia (Gifford, 2001; Gifford & Butler, 1997; Hall & Elvey, 1999; Johnson, 1997; Merskey & Bogduk, 1994).

While nerve trunk pain commonly has a fairly direct relationship to aggravating stimuli (Asbury & Fields, 1984; Hall & Elvey, 1999), dysesthetic pain can exhibit a variety of clinical behaviors (Butler, 2000; Devor & Seltzer, 1999; Gifford, 2001; Gifford & Butler, 1997). Patients may experience a burst of pain that coincides with the onset of the stimulus but subsides prior to the stimulus being removed. An example could involve a tennis player with peripheral neuropathic neck-arm pain experiencing a stab of pain when initiating cervical extension at the start of the ball toss for a serve and reporting that this sensation subsides even with further movement into extension to view the ball at the peak of the toss just prior to racquet contact. Symptoms provoked by movement may persist well after the stimulus has been removed and the patient has stopped the offending activity (i.e. hyperpathia). Dysesthetic pain

may sometimes be a response to the cumulative effect of several stimuli. For example, the tennis player described above with peripheral neuropathic neck-arm pain may not report the provocation of symptoms until after hitting multiple shots during a rally where the cervical spine has moved repeatedly relative to the trunk. Additionally, patients may occasionally experience stimulus-independent or spontaneous pain that may be paroxysmal in nature, or they may report that symptoms are worse during times of increased life stress. These perversions in the direct stimulus-response relationship are a reflection of a hyperexcitable nervous system displaying properties of increased afferent discharge from abnormal impulse generating sites (AIGS) (Baron, 2000; Devor & Seltzer, 1999; Harden, 2005; Woolf & Mannion, 1999). In spite of this variability, peripheral neuropathic pain associated with musculoskeletal disorders will generally exhibit a relatively consistent stimulus-response relationship (Butler, 2000; Gifford & Butler, 1997; Hall & Elvey, 1999).

Although commonly approximating dermatomes, cutaneous fields, or paths coursed by nerve trunks, the distribution of peripheral neuropathic pain associated with musculoskeletal dysfunction can also be variable (Butler, 2000; Gifford & Butler, 1997). Bove, Zaheen, and Bajwa (2005) stated that dermatomal charts may not be most appropriate for diagnosing lower limb radicular pain, because their sample of 25 patients with lumbar radiculopathy reported that symptoms experienced at rest or during passive straight leg raise (SLR) were deep in nature. The authors recommended that myotomal or sclerotomal charts may be more helpful in the diagnostic process. In patients with cervical nerve root irritation (i.e. no conduction deficit), Slipman et al. (1998) found that nearly 40% of symptomatic C6 nerve roots stimulated under fluoroscopy exhibited referred symptoms in the ulnar aspect of the hand. Variability in symptom location is partly related to the fact that the nervous system is a continuous tissue complex (Butler, 1991, 2000). Sensory and motor fibers display intradural connections between adjacent spinal cord segments (Tanaka, Yoshinori, An, Ikuta, & Yasuda, 2000), which means that neural injury near the intervertebral foramen can affect nerve fibers associated with more than one spinal cord level. Central nervous system neurons become sensitized after peripheral nerve injury and expand their receptive fields (Baron, 2000; Costigan & Woolf, 2000; Devor & Seltzer, 1999; Harden, 2005; Hasue, 1993; Mannion & Woolf, 2000; Woolf & Mannion, 1999), a process that can also explain why peripheral neuropathic symptoms may spread beyond typical dermatomal and cutaneous field boundaries (Butler, 2000; Gifford, 2001; Gifford & Butler, 1997; Shacklock, 1999).

## 2.2. *Physical examination findings*

A comprehensive assessment of any patient complaint requires examination of both nonneural and neural tissues.

Physical signs of peripheral neuropathic pain secondary to musculoskeletal dysfunction include increased mechanosensitivity in neural tissues combined with relevant impairments in surrounding musculoskeletal structures, and the severity of the injury dictates whether deficits in impulse conduction are present (Butler, 2000; Elvey, 1997; Gifford & Butler, 1997; Hall & Elvey, 1999). Specific concepts related to examination of nonneural structures and impulse conduction in neural tissues are beyond the scope of this paper and can be reviewed in any number of texts (e.g. Cyriax, 1982; Magee, 2002; Petty & Moore, 2001). This section focuses on physical examination findings that are indicative of increased neural tissue mechanosensitivity.

Neurodynamic tests (e.g. slump test, straight leg raise, upper limb neurodynamic tests) challenge the physical capabilities of the nervous system by using multijoint movements of the limbs and/or trunk to alter the length and dimensions of the nerve bed surrounding corresponding neural structures (Beith, Robins, & Richards, 1995; Butler, 1991, 2000; Coppieters, Stappaerts, Everaert, & Staes, 2001; Elvey, 1979, 1997; Hall & Elvey, 1999; Millesi, Zoch, & Rath, 1990; Shacklock, 1995b). Guidelines have been proposed to assist clinicians in identifying a 'positive' response to a neurodynamic test that would be considered suggestive of increased mechanosensitivity in neural tissues. First, the test reproduces the patient's symptoms or associated symptoms, and movement of a body segment remote from the location of symptoms provoked in the neurodynamic test position alters the response (i.e. structural differentiation). Second, there are differences in the test response between the involved and uninvolved sides or variations from what is known to be a normal response in asymptomatic subjects. These differences may include asymmetries in sensory response (i.e. aching, pulling, burning, tingling, etc.), range of motion, or resistance perceived by the examiner during application of the neurodynamic test, and these asymmetries are also altered by appropriate structural differentiation (Butler, 1991, 2000; Butler & Gifford, 1989a; Elvey, 1997; Shacklock, 2005). In some situations, the clinician may not be able to rely on asymmetry between limbs as a criterion for determining a 'positive' neurodynamic test. This can be illustrated in patients experiencing neck and/or arm symptoms after motor vehicle accident exhibiting hyperalgesic responses to neurodynamic testing in both upper limbs, an observation hypothesized to reflect the presence of central sensitization (Sterling, Treleaven, & Jull, 2002).

Alteration in resistance perceived by the examiner during neurodynamic testing is considered one of the most important signs of increased neural tissue mechanosensitivity (Hall & Elvey, 2004). Resistance perceived by the examiner is not necessarily a reflection of the viscoelastic behavior of the nervous system and its associated connective tissues. Protective muscle activity from the upper trapezius, brachialis, and biceps contributes to resistance encountered by the examiner during a median

biased upper limb neurodynamic test (ULNT) (Balster & Jull, 1997; Jaberzadeh, Scutter, & Nazeran, 2005; van der Heide, Allison, & Zusman, 2001). Similar activity from the hamstrings is associated with the resistance encountered during straight leg raise in asymptomatic and symptomatic subjects (Hall, Zusman, & Elvey, 1998). In contrast, changes in knee extension mobility secondary to releasing the neck flexion component of the slump test are not associated with changes in hamstring activity in asymptomatic subjects (Lew & Briggs, 1997).

The presence of a 'positive' neurodynamic test does not enable the clinician to identify the specific site of neural tissue injury; it merely indicates that the entire neural tissue tract loaded during the test is exhibiting an increased amount of mechanosensitivity (Butler, 2000). Neural tissues respond to movement through the development of strain, excursion, and stress in a non-uniform fashion (Grewal, Xu, Sotereanos, & Woo, 1996; Millesi, Zoch, & Reihnsner, 1995; Phillips, Smit, DeZoysa, Afoke, & Brown, 2004; Shacklock, 1995b). Consequently, neural structures will be subjected to different mechanical loads depending upon the order of joint movement during neurodynamic testing (Butler, 2000; Shacklock, 1995b), and the testing sequence has been shown to alter the mobility and/or symptom response during straight leg raise (Boland & Adams, 2000; Butler, 1991), slump (Johnson & Chiarello, 1997; Maitland, 1979, 1985; Pahor & Toppenberg, 1996), and a median nerve biased ULNT (Coppieters et al., 2001). The greatest mechanical challenge for a segment of neural tissue is thought to occur when the joint adjacent to the nerve is loaded first during the testing sequence, and the development of strain, excursion, and stress will spread to other portions of the neural tissue tract as more joint complexes participate in the movement (Shacklock, 1995b). The concept of neurodynamic sequencing may assist in determining whether a musculoskeletal peripheral neuropathic problem is in a more proximal or distal segment of the affected neural structure. The sequence of dorsiflexion and eversion prior to straight leg raise may be more effective for detecting a peripheral neuropathic component to heel pain (Meyer et al., 2002; Shacklock, 1995a). Applying a median nerve biased ULNT in a proximal to distal sequence has been shown to have clinical value for ruling out the presence of electrodiagnostically confirmed cervical radiculopathy (Wainner et al., 2003), but this same testing sequence was not helpful in identifying electrodiagnostically confirmed carpal tunnel syndrome (Wainner et al., 2005). The ultimate diagnostic value of neurodynamic sequencing needs to be ascertained by further validation studies, but until that time, clinicians may enhance their ability to detect relevant signs of increased neural tissue mechanosensitivity by altering the neurodynamic testing sequence to replicate the order of movement used by patients during symptomatic activities (Butler, 2000).

Nerve trunk palpation (with or without sustained manual compression) and isometric contraction (e.g. resisted isometric pronation as the elbow is gradually extended

targets the median nerve interface with the pronator teres) are other physical examination maneuvers used to identify enhanced mechanical sensitivity in neural structures (Butler, 2000; Elvey, 1997; Hall & Elvey, 1999; Novak & Mackinnon, 2005). Increased afferent discharge from AIGS and sensitized nervi nervorum are thought to mediate the symptom response associated with these provocative tests (Butler, 2000; Devor & Seltzer, 1999; Hall & Elvey, 1999). Provocation of symptomatic complaints during nerve palpation does not necessarily identify the site of neural tissue injury, because the entire neural tissue tract can become mechanically sensitive after injury to a particular nerve segment (Butler, 2000; Hall & Elvey, 1999). For example, uninjured portions of the tibial nerve in the popliteal fossa or posterior to the medial malleolus may be more sensitive to palpation in a patient with a low lumbar radicular problem. This spread of mechanosensitivity to uninjured portions of the involved neural tissue tract may be due to changes in axoplasmic flow and altered concentrations of ion channels that dictate the excitability and firing properties of affected nerve fibers (Butler, 2000; Devor & Seltzer, 1999), and nervi nervorum outside of the region of neural injury can become more sensitive to mechanical and chemical stimuli (Bove & Light, 1997; Elvey, 1997; Hall & Elvey, 1999). Additionally, hyperalgesic/allodynic responses in uninjured neural tissues may be the result of alterations in central nervous system processing of afferent information (i.e. central sensitization) (Butler, 2000; Devor & Seltzer, 1999; Gifford & Butler, 1997; Hall & Elvey, 1999; Shacklock, 1999; Zusman, 1992). In order to be more confident that a site of neural injury has been identified, the clinician should detect changes in tissue quality of the palpated nerve segment and adjacent nonneural structures in addition to any hyperalgesic/allodynic responses.

Positional testing of the spine or limbs may also impose mechanical loads on the nervous system by reducing the

space available for corresponding neural structures (e.g. extension or ipsilateral side-bending of the spine at the intervertebral foramina, Phalen's wrist flexion test at the carpal tunnel) (Farmer & Wisneski, 1994; Fujiwara, An, Lim, & Haughton, 2001; Gifford, 2001; Kitagawa et al., 2004; Novak & Mackinnon, 2005; Nuckley, Konodi, Raynak, Ching, & Mirza, 2002). These provocative tests provide evidence of increased mechanosensitivity in sensitized neural tissues through the same mechanisms discussed for palpation (i.e. nervi nervorum, AIGS, central sensitization).

In more minor peripheral neuropathic problems, some of the examination procedures described above may need to be combined to provide an adequate mechanical stimulus to detect alterations in neural tissue sensitivity. Examples might include palpating the superficial branch of the fibular nerve in a neurodynamically loaded position of straight leg raise with ankle plantarflexion and inversion, or adding sustained compression over the transverse carpal ligament with the wrist in a flexed position (i.e. carpal compression test with wrist flexion) (Butler, 2000; MacDermid & Wessel, 2004; Novak & Mackinnon, 2005). The therapist needs to use sound clinical reasoning skills to ensure that the vigor of the physical examination is appropriate for the suspected level of reactivity of the problem (Butler, 2000; Hall & Elvey, 1999; Shacklock, 2005).

As mentioned previously, the identification of relevant impairments in surrounding nonneural structures will point to a musculoskeletal cause of the peripheral neuropathic pain problem. The clinical behavior of musculoskeletal peripheral neuropathic pain will typically reflect a fairly direct stimulus-response relationship during the physical examination, but it can exhibit some of the aforementioned perversions in this relationship (e.g. burst of pain that stops prior to removal of the stimulus, persistence of pain after stimulus removed, onset of pain only after cumulative effect of several movements) (Butler, 2000; Gifford, 2001; Gifford

Box 1. Clinical features proposed to be associated with musculoskeletal peripheral neuropathic pain. Any combination of features may occur in the patient's presentation of symptoms. Please refer to text for details

- Superficial burning, stinging and paresthesia (i.e. dysesthetic pain)
- Distribution of symptoms may approximate peripheral cutaneous or dermatomal zones
- Deep aching, cramping (i.e. nerve trunk pain)
- Distribution of 'deep' symptoms may approximate myotomal or sclerotomal zones and/or pathways of involved nerve trunks
- Antalgic postures that correspond to unloading of sensitive neural tissues
- Active movement impairment
- Passive movement impairment that corresponds with active movement impairment
- Symptoms mechanically evoked by nerve compression and/or tension of appropriate neural structures that relate to active and passive movement impairments (perversions in this direct stimulus-response relationship may be present)
- Motor and/or sensory impairments that correspond to distribution of symptoms
- In ongoing problems, often difficult to ease symptoms for any length of time with rest or medications
- In ongoing problems, pain may behave as if having 'a mind of its own'

& Butler, 1997). Additionally, all of the physical examination findings should be consistent with subjective examination information that revealed the features of the symptomatic complaint and its history (Butler, 2000; Elvey, 1997; Hall & Elvey, 1999). The subjective and physical examination findings thought to be associated with musculoskeletal presentations of peripheral neuropathic pain have been summarized in Box 1.

### 3. Neurobiological mechanisms

Mechanical and chemical irritation can lead to musculoskeletal neural tissue injury. Repetitive compressive, tensile, friction, and vibration forces acting near anatomically narrow tissue spaces through which neural structures pass can cause mechanical irritation (Butler, 1991; Sunderland, 1991). Injured somatic tissues adjacent to nerve structures release inflammatory substances that can chemically irritate neural tissues (Cavanaugh, 1995; Garfin, Rydevik, & Brown, 1991; Garfin, Rydevik, Lind, & Massie, 1995; Murata, Rydevik, Takahashi, Larsson, & Olmarker, 2005; Takahashi, Yabuki, Aoki, & Kikuchi, 2003; Takebayashi, Cavanaugh, Ozaktay, Kallakuri, & Chen, 2001). Pathophysiological and pathomechanical responses to nerve injury affect the vascular, connective tissue, and impulse conducting tissue components of the nervous system and lead to the neurobiological mechanisms responsible for the positive and negative symptoms associated with musculoskeletal peripheral neuropathic pain.

#### 3.1. Sensitization of neural connective tissue nociceptors

Compromise in intraneural circulation appears to be the first step in the pathophysiological cascade of nerve injury. Mechanical or chemical stimuli that exceed the physical capabilities of neural tissues induce venous congestion, and therefore, impede intraneural circulation and axoplasmic flow (Greening & Lynn, 1998; Hasue, 1993; Kobayashi, Yoshizawa, & Nakai, 2000; Lundborg & Dahlin, 1992; Ogata & Naito, 1986; Olmarker & Rydevik, 1991; Parke & Whalen, 2002; Rempel, Dahlin, & Lundborg, 1999; Rydevik, Brown, & Lundborg, 1984). Subsequent hypoxia and alterations in microvascular permeability cause an inflammatory response in nerve trunks and dorsal root ganglia (DRG) that leads to subperineurial edema and increased endoneurial fluid pressure (Hasue, 1993; Igarashi, Yabuki, Kikuchi, & Myers, 2005; Kobayashi et al., 2000; Lundborg, 1988; Lundborg, Myers, & Powell, 1983; Mackinnon, Dellon, Hudson, & Hunter, 1984; O'Brien et al., 1987; Parke & Whalen, 2002; Rempel et al., 1999; Rydevik, Myers, & Powell, 1989; Triano & Luttges, 1982; Yabuki, Onda, Kikuchi, & Myers, 2001). Neuropeptides released from mechanically irritated *nervi nervorum* and pro-inflammatory mediators produced by immune cell activation contribute to this inflammatory response (Gazda

et al., 2001; Sauer, Bove, Averbek, & Reeh, 1999; Watkins & Maier, 2004). Once neural connective tissues are inflamed, nociceptors in the *nervi nervorum* and sinuvertebral nerves will become sensitized to mechanical and chemical stimuli, contributing to the enhanced mechanosensitivity observed in peripheral neuropathic pain (i.e. nerve trunk pain) (Baron, 2000; Bove & Light, 1997; Devor & Seltzer, 1999; Gifford & Butler, 1997; Greening & Lynn, 1998; Hall & Elvey, 1999; Kallakuri et al., 1998; Zochodne, 1993).

Endoneurial edema persists because the perineurial diffusion barrier does not allow inflammatory exudates to escape (Lundborg, 1988; Lundborg & Dahlin, 1992; Lundborg et al., 1983; Murphy, 1977). Persistent endoneurial edema leads to intraneural fibrosis and compromises the viscoelastic properties of neural connective tissues (Beel, Groswald, & Luttges, 1984; Millesi et al., 1995; Rempel et al., 1999). When intraneural fibrosis has reduced the extensibility of neural connective tissues, already sensitized nociceptors in the *nervi nervorum* and sinuvertebral nerves will be subjected to more intense mechanical stimulation, because fibrotic connective tissues can no longer effectively attenuate the mechanical loads associated with daily and sport activities, or physical examination maneuvers (Bove & Light, 1997; Millesi et al., 1995; Sunderland, 1990). Consequently, intraneural fibrosis can further contribute to increased nociceptive input from *nervi nervorum* and sinuvertebral nerves in peripheral neuropathic pain states.

#### 3.2. Formation of abnormal impulse generating sites (AIGS)

An injured segment of peripheral nerve and its associated DRG may develop the ability to repeatedly generate their own impulses (Devor & Seltzer, 1999). They are referred to as AIGS, because these portions of a sensory neuron do not normally initiate impulses (Devor & Seltzer, 1999). The main features of AIGS are mechanosensitivity, chemosensitivity, and spontaneous firing (Butler, 2000; Devor & Seltzer, 1999).

Ion channels are proteins produced in the cell body that insert into the axon membrane and determine neuron excitability. The ensemble of ion channels is normally remodeled on a continual basis so that an afferent neuron maintains an appropriate level of sensitivity to surrounding stimuli (Bear, Connors, & Paradiso, 2001; Costigan & Woolf, 2000; Devor & Seltzer, 1999; Koester & Siegelbaum, 1995). Nerve injury alters gene expression within the cell body (Baron, 2000; Costigan & Woolf, 2000), which means that the type and number of ion channels in the axon membrane change so that neurons fire more readily in response to mechanical and chemical stimuli (Baron, 2000; Devor & Seltzer, 1999; Harden, 2005; Woolf & Mannion, 1999). Impairments in axoplasmic flow lead to the accumulation of ion channels in areas of nerve injury (Devor & Seltzer, 1999). Since ion channels insert into portions of the axon membrane not covered by myelin,

DRG, areas of myelin thinning, and areas of segmental demyelination provide additional opportunities for the abnormal accumulation of mechanosensitive and chemosensitive ion channels (Amir & Devor, 1993; Calvin, Devor, & Howe, 1982; Chen & Devor, 1998; Devor & Seltzer, 1999). All of these areas are now capable of generating an increased amount of nociceptive input that contributes to the symptoms and signs of musculoskeletal peripheral neuropathic pain (i.e. dysesthetic pain).

The type and number of ion channels dictate which stimuli will evoke symptoms in musculoskeletal peripheral neuropathic pain. Normally innocuous lengthening, pinching, or friction forces become capable of provoking symptoms when concentrations of mechanosensitive ion channels are increased. Repetitive movement (e.g. soccer player with lower extremity peripheral neuropathic pain provoked with running) or sustained positioning (e.g. cyclist that aggravates upper extremity peripheral neuropathic symptoms with arms in certain positions on the handlebars) can evoke symptoms from AIGS packed with ischemo-sensitive channels, and inflammatory chemicals from injured neural or nonneural tissues can stimulate chemosensitive channels (Butler, 2000; Devor & Seltzer, 1999; Gifford, 2001; Gifford & Butler, 1997). Emotional stress can exacerbate symptoms of nerve injury (Butler, 2000; Gifford, 2001), partly because the chemicals associated with stress (e.g. adrenaline, noradrenaline) are capable of stimulating AIGS (Baron, 2000; Devor & Seltzer, 1999; Greening & Lynn, 1998; Hasue, 1993; Shacklock, 1995b). AIGS also exhibit spontaneous activity (Devor & Seltzer, 1999), which corresponds to patient reports that symptoms sometimes occur independent of any type of stimulus (Gifford, 2001; Gifford & Butler, 1997). Axonal mechanosensitivity and spontaneous discharge secondary to neural inflammation appear to develop primarily in A-delta and C fibers that innervate deep structures (Bove, Ransil, Lin, & Leem, 2003), which may provide a partial explanation for the aforementioned observation that musculoskeletal peripheral neuropathic pain is often described as deep in nature (Bove et al., 2005).

When the mid-portion of afferent axons or DRG generate their own impulses, the messages travel toward the spinal cord and toward the periphery. Impulses in afferent neurons that travel toward the periphery are referred to as antidromic impulses. Upon reaching the peripheral terminals of afferent neurons, antidromic impulses cause the release of pro-inflammatory chemicals into the target tissue, a process referred to as neurogenic inflammation (Daemen et al., 1998; White, 1997). Therefore, an injured segment of neural tissue can have a detrimental impact on the physical health of the target tissue it innervates (Butler, 2000; Shacklock, 1995a). The process of neurogenic inflammation accounts for the earlier statement that peripheral neuropathic pain may have a role in some presentations of musculoskeletal syndromes such as lateral epicondylalgia, achilles tendinosis, heel pain, and inversion ankle sprains.

### 3.3. Central sensitization and the neuromatrix

As mentioned previously, augmentation of sensory processing within the central nervous system (i.e. central sensitization) can contribute to the distribution and stimulus-response behavior of musculoskeletal peripheral neuropathic pain. Central sensitization develops because of alterations in afferent input, changes in chemicals transported from the periphery, sprouting of low threshold afferent fibers into superficial layers of the dorsal horn involved in nociception, immune activation, and alterations in central descending control mechanisms (i.e. disinhibition) (Baron, 2000; Gracely, Lynch, & Bennett, 1992; Harden, 2005; Nakamura & Myers, 2000; Rutkowski, Winkelstein, Hickey, Pahl, & DeLeo, 2002; Wall, 1991; Watkins & Maier, 2004; Woolf, 2004; Woolf & Mannion, 1999). An appreciation of the latter is important for understanding that the brain is not a passive recipient of afferent information (Melzack, 1996, 2005); it actively modifies the input it receives through descending control mechanisms (Shacklock, 1999).

A recent definition of pain acknowledges the active role the brain has in any clinical pain state. Pain is produced by the brain when it perceives that body tissues are in danger and a response is required (Moseley, 2003a). Areas of the brain associated with sensory perception, emotion, attention, cognition, and motor planning are activated during a pain experience (Butler, 2000; Melzack, 1996, 2005; Moseley, 2003a; Vogt, 2005), and this neural circuitry has been referred to as the pain neuromatrix (Melzack, 1996, 2005; Moseley, 2003a). The multiple brain areas involved in the pain neuromatrix provide a partial explanation for why psychosocial issues such as distress, mistaken beliefs about the nature of the pain, and fear of activity or reinjury can exacerbate pain and slow recovery (Butler, 2000; Main & Watson, 1999; Moseley, 2003a; Shacklock, 1999; Vlaeyen & Linton, 2000; Zusman, 2002). An understanding of the pain neuromatrix can expand the options available to the therapist in the management of musculoskeletal peripheral neuropathic pain, because it underscores the need to address the patient's pain behavior and distress in addition to the nociceptive component of the problem (Butler, 2000; Main & Watson, 1999; Moseley, 2003a; Shacklock, 1999).

### 3.4. Impairment of impulse conduction

In addition to leading to intraneural fibrosis, the amount and duration of endoneurial edema is directly correlated with more marked degradation in myelin content and axon structure (Rempel et al., 1999). It has been hypothesized that these myelin changes are consequences of impaired axoplasmic flow and altered function of the cell body (Dahlin, Nordborg, & Lundborg, 1987). There will be varying degrees of pathology present in adjacent fascicles within the affected nerve segment (Greening & Lynn, 1998; Mackinnon et al., 1984; O'Brien et al., 1987).

Consequently, a patient may report significant peripheral neuropathic pain complaints, but clinical examination of impulse conduction and electrodiagnostic testing may be normal (Mackinnon, 1992). Since electrodiagnostic testing cannot be specific to individual nerve fascicles, normal fascicles account for normal electrodiagnostic tests while adjacent abnormal fascicles and inflamed neural connective tissues can be responsible for symptom complaints (Greening & Lynn, 1998; Mackinnon, 1992). It is important for the clinician to appreciate that many patients presenting with musculoskeletal peripheral neuropathic pain may exhibit any combination of the positive symptoms of pain, paresthesia, dysesthesia, and spasm with no clinical evidence of the negative symptoms of hypoesthesia or

anesthesia and weakness (Butler, 2000; Greening & Lynn, 1998; Hall & Elvey, 1999). In other words, these patients will have a primary presentation of increased neural tissue mechanosensitivity. A summary of the pathophysiology and neurobiology associated with musculoskeletal peripheral neuropathic pain is shown in Fig. 1.

#### 4. Management and clinical evidence

The broad goals for managing musculoskeletal presentations of peripheral neuropathic pain are to reduce the mechanosensitivity of the nervous system and restore its normal capabilities for movement. The principles of

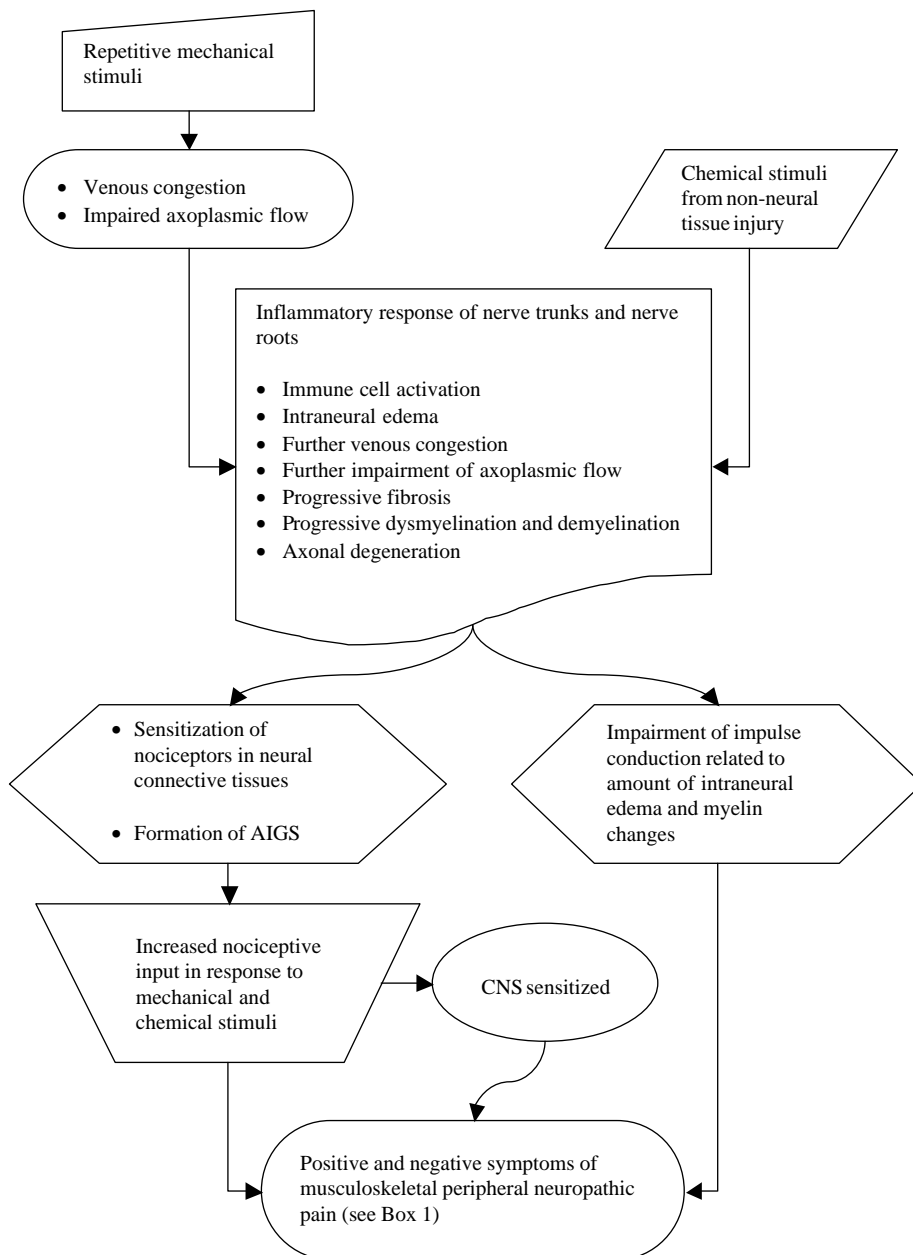


Fig. 1. Summary of pathophysiology and neurobiology associated with the development of musculoskeletal peripheral neuropathic pain.

management discussed in the following sections can only be applied within the context of a clinical reasoning framework where the therapist employs a system of reassessment to judge the impact that intervention strategies have on the nonneural and neural components of the problem (Butler, 1991, 2000; Butler & Gifford, 1989b; Hall & Elvey, 1999; Shacklock, 2005). Relevant clinical evidence from the published literature has been integrated into the discussion.

#### 4.1. Education in neurodynamics and neurobiology

Patients should understand that the nervous system is well designed to move during daily activities, and an introduction to neurobiomechanical concepts can make it easier to explain why certain movements or physical examination maneuvers have become symptomatic. Appreciating the mechanical continuity of the nervous system may also assist patients in understanding why movement of body parts remote from the site of symptoms may be used as a treatment strategy to mobilize neural tissues. The impact movement has on the nervous system is not only mechanical; discussion should include explanations of how intraneural circulation, axoplasmic flow, and nociceptors in neural connective tissues can be affected by mechanical loading (Shacklock, 1995b). The interdependence between the mechanics and physiology of the nervous system is termed neurodynamics (Shacklock, 1995b), and educating patients in neurodynamic concepts sets a foundation for discussing the aforementioned neurobiological mechanisms associated with the development of musculoskeletal peripheral neuropathic pain.

Educating patients about the neurobiological mechanisms involved in the clinical behavior of their presentation of peripheral neuropathic pain can reduce the threat value associated with their pain experience and alter any unhelpful beliefs they may have about their problem (i.e. may influence emotional and cognitive components of the pain neuromatrix) (Butler, 2000; Moseley, 2003a; Shacklock, 1999). Patients are very capable of understanding information on the neurobiology of pain (Moseley, 2003b), and Butler & Moseley (2003) have detailed a method for explaining this information in patient-friendly language. Evidence exists, for example, that presenting this information to patients with low back pain can make immediate changes in straight leg raise mobility that correlate directly with reductions in unhelpful beliefs and attitudes about pain (Moseley, 2004). It is proposed that neurobiology education sets a scene within which clinician- or patient-generated therapeutic movement can be more effective (Butler, 2000; Moseley, 2003a; Shacklock, 1999).

#### 4.2. Nonneural tissue impairments

Impairments in nonneural tissues that provide clinical evidence for a musculoskeletal cause of peripheral

neuropathic pain need to be addressed during management (Butler, 1991, 2000; Butler & Gifford, 1989b; Hall & Elvey, 1999; Shacklock, 2005). Ensuring that adjacent nonneural structures are functioning in an optimal fashion can reduce the mechanical forces these structures place on sensitive neural tissues (Butler, 2000; Hall & Elvey, 1999), thereby theoretically reducing nociceptive input from sensitized *nervi nervorum* and AIGS (Butler, 2000). For example, restoring optimal function in the superior and inferior tibiofibular articulations may assist in reducing nociceptive input from a fibular nerve that has become mechanically sensitive after an inversion ankle injury. Given the mechanical continuity of the nervous system, the clinician may need to examine nonneural structures along the entire neural tissue tract exhibiting increased mechanosensitivity (Butler, 2000). Intervention techniques may take the form of joint mobilization, soft-tissue work, taping to unload sensitive neural structures, or retraining neuromuscular control. An example of the latter was presented in a case report by Klingman (1999) addressing a patient with lumbar-leg symptoms during running and signs of neural tissue mechanosensitivity. Management incorporated calf stretching and weightbearing exercises for the gluteus medius to reduce overpronation and improve frontal plane control of the pelvis. These interventions could facilitate relative unloading of mechanically sensitive lower extremity neural tissues associated with the tibial branch of the sciatic tract.

Addressing nonneural tissue impairments can often be a starting point for management when clinicians are less familiar with neural tissue mobilization, and the effect these techniques have on findings of neural tissue mechanosensitivity should be monitored closely (Butler, 1991, 2000). Smaller scale clinical studies have shown that manual therapy techniques biased toward articular structures are more effective than no treatment for reducing pain and the need for surgery in patients with carpal tunnel syndrome ( $n=21$ ) (Tal-Akabi & Rushton, 2000) and for reducing pain and self-reported disability in patients with neck-arm pain of neurogenic origin ( $n=30$ ) (Allison, Nagy, & Hall, 2002). Lack of adequate improvement in response to nonneural tissue management indicates the need to progress toward direct neural tissue mobilization techniques.

#### 4.3. Neural tissue mobilization

Neural tissue mobilization techniques are passive or active movements that focus on restoring the ability of the nervous system to tolerate the normal compressive, friction, and tensile forces associated with daily and sport activities. It is hypothesized that these therapeutic movements can have a positive impact on symptoms by improving intraneural circulation, axoplasmic flow, neural connective tissue viscoelasticity, and by reducing sensitivity of AIGS (Butler, 2000; Shacklock, 2005), but these biologically plausible contentions have not been validated. These techniques may



also be able to reduce unwanted fear of movement when provided in conjunction with appropriate neurobiology education, and therefore, they may reduce the reactivity of the pain neuromatrix (Butler, 2000; Moseley, 2003a). Clinical studies exploring neural tissue mobilization techniques that are cited in the following sections have commonly utilized changes in patients' self-reports of pain, disability, or physical signs of mechanosensitivity as outcomes to detect an effect on the peripheral neuropathic pain state.

#### 4.4. Gliding techniques

Gliding techniques, or 'sliders', are neurodynamic maneuvers that attempt to produce a sliding movement between neural structures and adjacent nonneural tissues, and they are executed in a non-provocative fashion (Butler,

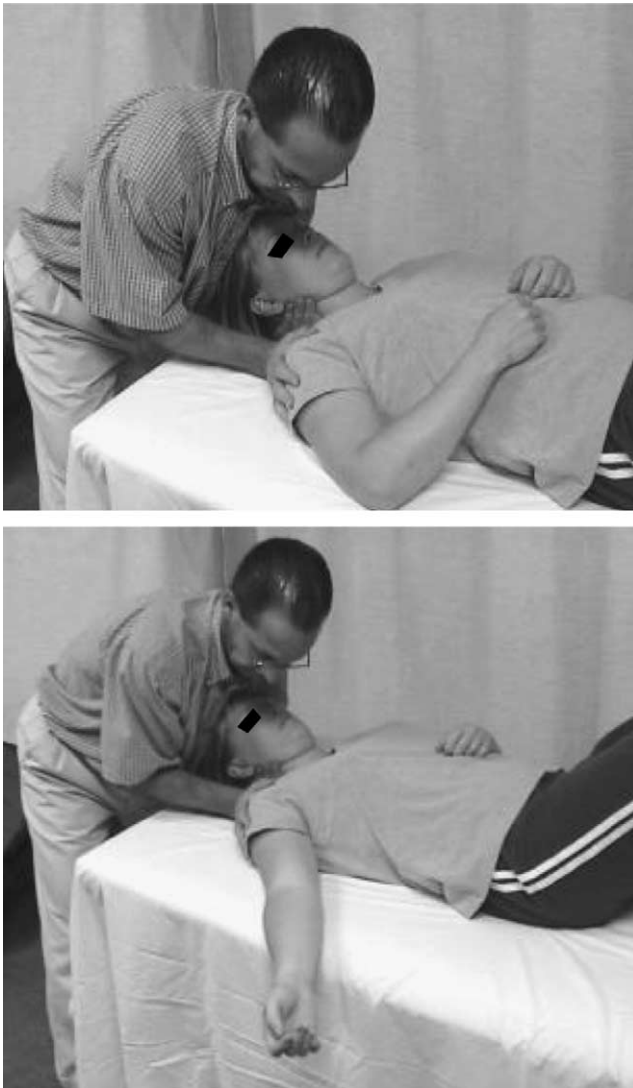

Fig. 2. Cervical lateral glide technique. The head and cervical spine are translated in an oscillatory fashion away from the affected upper extremity that can be placed in a neurodynamically unloaded (top) or loaded (bottom) position depending upon the desired vigor of treatment (Elvey, 1986).

2000; Shacklock, 2005). A cervical lateral glide technique (Elvey, 1986; Vicenzino, Neal, Collins, & Wright, 1999) (Fig. 2) has been shown to produce immediate reductions in pain and signs of neural tissue mechanosensitivity in patients with lateral epicondylalgia (Vicenzino, Collins, & Wright, 1996) or neurogenic neck-arm pain (Coppieters, Stappaerts, Wouters, & Janssens, 2003a,b). Allison et al. (2002) incorporated cervical lateral glide and shoulder girdle oscillation techniques (Elvey, 1986) in their randomized controlled trial on the treatment of patients with neurogenic neck-arm pain. The program utilizing these neural gliding techniques was more effective than no intervention for reducing pain and self-reported disability, and it was more effective than a program incorporating manual therapy techniques directed at the articular structures of the shoulder and thoracic spine in reducing pain at the completion of treatment. A non-randomized clinical trial demonstrated that adding nerve and tendon gliding techniques to conservative management reduced the

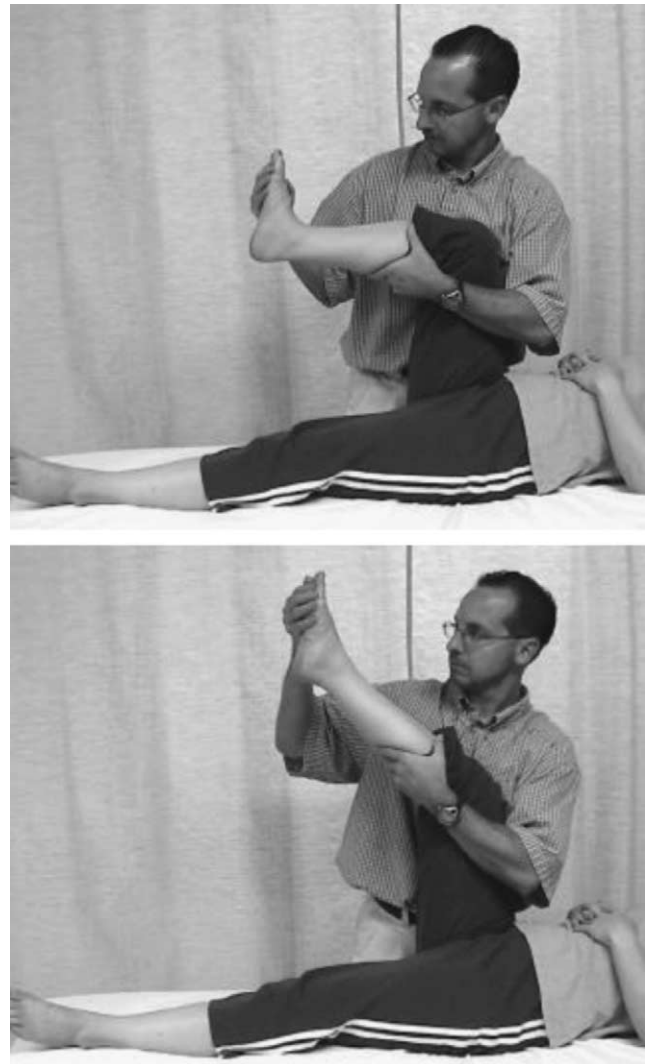


Fig. 3. Passive neurodynamic 'slider' technique biased toward the tibial branch of the sciatic tract.

need for carpal tunnel surgery by nearly 30% (Rozmaryn et al., 1998), but a more recent randomized clinical trial found that supplementing a program of splinting with nerve and tendon gliding exercises did not provide any additional improvements in severity of symptoms or function in patients with carpal tunnel syndrome (Akalin et al., 2002). Examples of neurodynamic ‘sliders’ are illustrated in Figs. 3 and 4 and have been well described by Butler (2005) and Shacklock (2005).

#### 4.5. Tensile loading techniques

As the name implies, the purpose of neurodynamic tensile loading techniques is to restore the physical capabilities of neural tissues to tolerate movements that lengthen the corresponding nerve bed. It is important to emphasize that tensile loading techniques are not stretches; these neurodynamic maneuvers are performed in an oscillatory fashion so as to gently engage resistance to movement that is usually associated with protective muscle activity (Butler, 2000; Shacklock, 2005). The vigor of technique may be adjusted to elicit gentle stretching sensations or to evoke mild symptoms in rhythm with each oscillation (Butler, 2000). Tensile loading techniques



Fig. 4. Active neurodynamic ‘slider’ technique biased toward the median nerve.

are more aggressive than neurodynamic ‘sliders’ (Butler, 2000; Shacklock, 2005), and they are not indicated in patients with clinical evidence of impairments in impulse conduction.

Tal-Akabi and Rushton (2000) utilized neural tissue mobilization techniques in their randomized clinical trial on patients with carpal tunnel syndrome, but they did not specify whether ‘sliders’ or tensile loading techniques were



Fig. 5. Active neurodynamic tensile loading technique biased toward the tibial branch of the sciatic tract in a modified slump position.

used. Neural tissue mobilization was more effective than no treatment for reducing pain and the need for carpal tunnel surgery, but neurodynamic techniques were no more effective than joint mobilization techniques that facilitated horizontal extension of the carpal bones. A clinical trial on Australian Rules football players with grade 1 hamstring strains and positive findings during the slump test demonstrated that supplementing a conservative management program with neurodynamic tensile loading techniques led to a faster return to competition (Kornberg & Lew, 1989). Tensile loading techniques, with or without ‘sliders’, have also been used successfully in case studies or single-subject design studies describing patients with signs of increased neural tissue mechanosensitivity in combination with lumbar-lower extremity symptoms (Cleland, Hunt, & Palmer, 2004; George, 2002; Klingman, 1999), heel pain (Meyer et al., 2002; Shacklock, 1995a), lateral epicondylalgia (Ekstrom & Holden, 2002), and cubital tunnel syndrome (Coppieters, Bartholomeeusen, & Stappaerts, 2004). In contrast, a randomized controlled trial clearly demonstrated that neural tissue mobilization did not provide any additional benefit to standard postoperative care in patients who had undergone lumbar discectomy, laminectomy, or fusion (Scrimshaw & Maher, 2001). Examples of neurodynamic tensile loading techniques are

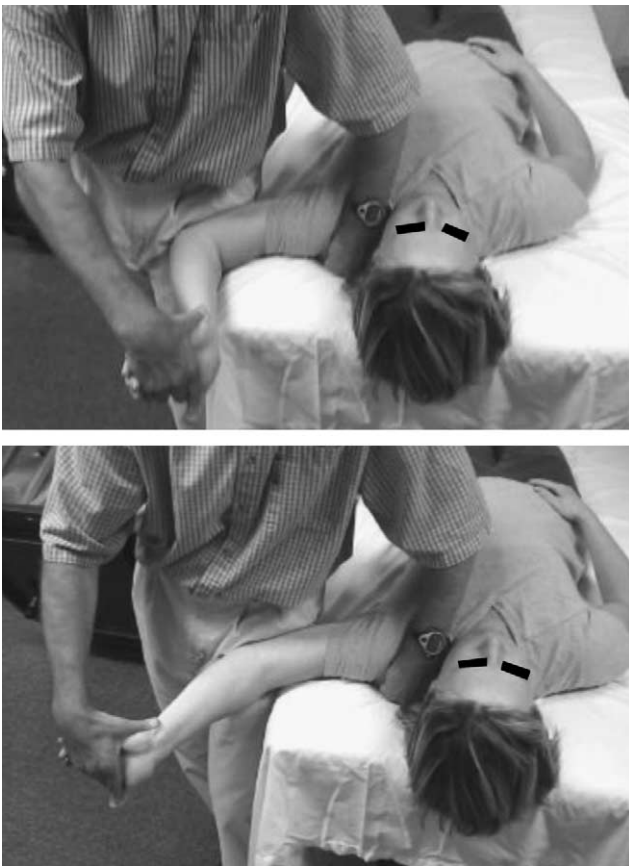

Fig. 6. Passive neurodynamic tensile loading technique biased toward the median nerve.

presented in Figs. 5 and 6 and have been described in detail by Butler (2005) and Shacklock (2005).

#### 4.6. Combined techniques

While nonneural and neurodynamic intervention techniques have been described separately, they may need to be combined in patients with less reactive peripheral neuropathic symptoms of musculoskeletal origin. An example of a combined intervention technique was presented in the previously mentioned case study by Klingman (1999) describing a patient with lumbar-leg pain during running with signs of neural tissue mechanosensitivity. The patient was placed in prone with the symptomatic limb off the side of the table in a partial straight leg raise position, and unilateral posterior-anterior pressures were applied to the hypomobile motion segments in the lumbar spine. The choice and progression of any of these intervention techniques will be based on the results of reassessment of all of the components of the patient's presentation of musculoskeletal peripheral neuropathic pain (Butler, 2000).

## 5. Conclusions

The positive and negative symptoms associated with musculoskeletal presentations of peripheral neuropathic pain are produced by sensitized nociceptors in neural connective tissues, hypersensitive AIGS, a sensitized pain neuromatrix, myelin changes, and axonal degeneration. It is proposed that conservative management incorporating neurodynamic and neurobiology education, nonneural tissue interventions, and neurodynamic mobilization techniques can be effective in addressing musculoskeletal peripheral neuropathic pain states. While a small amount of clinical evidence lends some support to this proposal, much more clinical research is necessary to identify those patients with peripheral neuropathic pain that will respond most favorably to neurodynamic mobilization techniques and clarify specific treatment parameters that will be most effective. Regardless of the results of this future research, conservative care will always need to be grounded in sound clinical reasoning so that interventions can be individualized to address the nuances of each patient's presentation of musculoskeletal peripheral neuropathic pain.

## References

- Akalin, E., El, O., Peker, O., Senocak, O., Tamci, S., Gulbahar, S., et al. (2002). Treatment of carpal tunnel syndrome with nerve and tendon gliding exercises. *American Journal of Physical Medicine and Rehabilitation*, 81, 108–113.
- Allison, G., Nagy, B., & Hall, T. (2002). A randomized clinical trial of the manual therapy for cervico-brachial pain syndrome: A pilot study. *Manual Therapy*, 7, 95–102.

- Amir, R., & Devor, M. (1993). Ongoing activity in neuroma afferents bearing retrograde sprouts. *Brain Research*, *630*, 283–288.
- Asbury, A., & Fields, H. (1984). Pain due to peripheral nerve damage: An hypothesis. *Neurology*, *34*, 1587–1590.
- Balster, S., & Jull, G. (1997). Upper trapezius muscle activity during the brachial plexus tension test in asymptomatic subjects. *Manual Therapy*, *2*, 144–149.
- Baron, R. (2000). Peripheral neuropathic pain: From mechanisms to symptoms. *The Clinical Journal of Pain*, *16*(Suppl.), S12–S20.
- Bear, M., Connors, B., & Paradiso, M. (2001). *Neuroscience: Exploring the brain* (2nd ed.). Baltimore, MD: Lippincott/Williams & Wilkins.
- Beel, J., Groszwald, D., & Luttgies, M. (1984). Alterations in the mechanical properties of peripheral nerve following crush injury. *Journal of Biomechanics*, *17*, 185–193.
- Beith, I., Robins, E., & Richards, P. (1995). An assessment of the adaptive mechanisms within and surrounding the peripheral nervous system, during changes in nerve bed length resulting from underlying joint movement. In M. Shacklock (Ed.), *Moving in on pain* (pp. 194–203). Sydney, Australia: Butterworth Heinemann.
- Boland, R., & Adams, R. (2000). Effects of ankle dorsiflexion on range and reliability of straight leg raising. *Australian Journal of Physiotherapy*, *46*, 191–200.
- Bove, G., & Light, A. (1997). The nervi nervorum: Missing link for neuropathic pain? *Pain Forum*, *6*, 181–190.
- Bove, G., Ransil, B., Lin, H., & Leem, J. (2003). Inflammation induces ectopic mechanical sensitivity in axons of nociceptors innervating deep tissues. *Journal of Physiology*, *90*, 1949–1955.
- Bove, G., Zaheen, A., & Bajwa, Z. (2005). Subjective nature of lower limb radicular pain. *Journal of Manipulative and Physiological Therapeutics*, *28*, 12–14.
- Butler, D. (1991). *Mobilisation of the nervous system*. Melbourne, Australia: Churchill Livingstone.
- Butler, D. (2000). *The sensitive nervous system*. Adelaide, Australia: Noigroup Publications.
- Butler, D. (Ed.). (2005). *The neurodynamic techniques*. Adelaide, Australia: Noigroup Publications.
- Butler, D., & Gifford, L. (1989a). The concept of adverse mechanical tension in the nervous system. Part 1: Testing for 'dural tension'. *Physiotherapy*, *75*, 622–629.
- Butler, D., & Gifford, L. (1989b). The concept of adverse mechanical tension in the nervous system. Part 2: Examination and treatment. *Physiotherapy*, *75*, 629–636.
- Butler, D., & Moseley, G. (2003). *Explain pain*. Adelaide, Australia: Noigroup Publications.
- Calvin, W., Devor, M., & Howe, J. (1982). Can neuralgias arise from minor demyelination? Spontaneous firing, mechanosensitivity, and after-discharge from conducting axons. *Experimental Neurology*, *75*, 755–763.
- Cavanaugh, J. (1995). Neural mechanisms of lumbar pain. *Spine*, *20*, 1804–1809.
- Chen, Y., & Devor, M. (1998). Ectopic mechanosensitivity in injured sensory axons arises from the site of spontaneous electrogenesis. *European Journal of Pain*, *2*, 165–178.
- Cleland, J., Hunt, G., & Palmer, S. (2004). Effectiveness of neural mobilization in the treatment of a subject with lower extremity peripheral neurogenic pain: A single-case design. *Journal of Manual and Manipulative Therapy*, *12*, 143–152.
- Coppieters, M., Bartholomeeusen, K., & Stappaerts, K. (2004). Incorporating nerve-gliding techniques in the conservative treatment of cubital tunnel syndrome. *Journal of Manipulative and Physiological Therapeutics*, *27*, 560–568.
- Coppieters, M., Stappaerts, K., Everaert, D., & Staes, F. (2001). Addition of test components during neurodynamic testing: Effect on range of motion and sensory responses. *Journal of Orthopaedic and Sports Physical Therapy*, *31*, 226–237.
- Coppieters, M., Stappaerts, K., Wouters, L., & Janssens, K. (2003a). Aberrant protective force generation during neural provocation testing and the effect of treatment in patients with neurogenic cervicobrachial pain. *Journal of Manipulative and Physiological Therapeutics*, *26*, 99–106.
- Coppieters, M., Stappaerts, K., Wouters, L., & Janssens, K. (2003b). The immediate effects of a cervical lateral glide treatment technique in patients with neurogenic cervicobrachial pain. *Journal of Orthopaedic and Sports Physical Therapy*, *33*, 369–378.
- Costigan, M., & Woolf, C. (2000). Pain: Molecular mechanisms. *The Clinical Journal of Pain*, *1*(3 Suppl. 1), 35–44.
- Cyriax, J. (1982). *Textbook of orthopaedic medicine, volume 1: Diagnosis of soft tissue lesions* (8th ed.). London: Bailliere Tindall.
- Daemen, M., Kurvers, H., Kitslaar, P., Slaaf, D., Bullens, P., & Van den Wildenberg, F. (1998). Neurogenic inflammation in an animal model of neuropathic pain. *Neurological Research*, *20*, 41–45.
- Dahlin, L., Nordborg, C., & Lundborg, G. (1987). Morphologic changes in nerve cell bodies induced by experimental graded nerve compression. *Experimental Neurology*, *95*, 611–621.
- Devor, M., & Seltzer, Z. (1999). Pathophysiology of damaged nerves in relation to chronic pain. In P. Wall & R. Melzack (Eds.), *Textbook of pain* (4th ed., pp. 129–164). Edinburgh: Churchill Livingstone.
- Elvey, R. (1986). Treatment of arm pain associated with abnormal brachial plexus tension. *Australian Journal of Physiotherapy*, *32*, 225–230.
- Elvey, R. (1997). Physical evaluation of the peripheral nervous system in disorders of pain and dysfunction. *Journal of Hand Therapy*, *10*, 122–129.
- Farmer, J., & Wisneski, R. (1994). Cervical spine nerve root compression: An analysis of neuroforaminal pressures with varying head and arm positions. *Spine*, *19*, 1850–1855.
- Fujiwara, A., An, H., Lim, T., & Haughton, V. (2001). Morphologic changes in the lumbar intervertebral foramen due to flexion-extension, lateral bending, and axial rotation. *Spine*, *26*, 876–882.
- Garfin, S., Rydevik, B., & Brown, R. (1991). Compressive neuropathy of spinal nerve roots: A mechanical or biological problem? *Spine*, *16*, 162–166.
- Garfin, S., Rydevik, B., Lind, B., & Massie, J. (1995). Spinal nerve root compression. *Spine*, *20*, 1810–1820.
- Gazda, L., Milligan, E., Hansen, M., Twining, C., Poulos, N., Chacur, M., et al. (2001). Sciatic inflammatory neuritis (SIN): Behavioral allodynia is paralleled by peri-sciatic proinflammatory cytokine and superoxide production. *Journal of the Peripheral Nervous System*, *6*, 111–129.
- George, S. (2002). Characteristics of patients with lower extremity symptoms treated with slump stretching: A case series. *Journal of Orthopaedic and Sports Physical Therapy*, *32*, 391–398.
- Gifford, L. (2001). Acute low cervical nerve root conditions: Symptom presentations and pathobiological reasoning. *Manual Therapy*, *6*, 106–115.
- Gifford, L., & Butler, D. (1997). The integration of pain sciences into clinical practice. *Journal of Hand Therapy*, *10*, 86–95.
- Gracely, R., Lynch, S., & Bennett, G. (1992). Painful neuropathy: Altered central processing maintained dynamically by peripheral input. *Pain*, *51*, 175–194.
- Greening, J., & Lynn, B. (1998). Minor peripheral nerve injuries: An underestimated source of pain? *Manual Therapy*, *3*, 187–194.
- Grewal, R., Xu, J., Sotereanos, D., & Woo, S. (1996). Biomechanical properties of peripheral nerves. *Hand Clinics*, *12*, 195–204.
- Hall, T., & Elvey, R. (1999). Nerve trunk pain: Physical diagnosis and treatment. *Manual Therapy*, *4*, 63–73.
- Hall, T., & Elvey, R. (2004). Management of mechanosensitivity of the nervous system in spinal pain syndromes. In J. Boyling & G. Jull (Eds.), *Grieve's modern manual therapy: The vertebral column* (3rd ed., pp. 413–431). Edinburgh: Churchill Livingstone.
- Kornberg, C., & Lew, P. (1989). The effect of stretching neural structures on grade one hamstring injuries. *Journal of Orthopaedic and Sports Physical Therapy*, *10*, 481–487.
- Lew, P., & Briggs, C. (1997). Relationship between the cervical component of the slump test and change in hamstring muscle tension. *Manual Therapy*, *2*, 98–105.

- Lundborg, G. (1988). Intraneural microcirculation. *Orthopedic Clinics of North America*, 19, 1–12.
- Lundborg, G., & Dahlin, L. (1992). The pathophysiology of nerve compression. *Hand Clinics*, 8, 215–227.
- Lundborg, G., Myers, R., & Powell, H. (1983). Nerve compression injury and increased endoneurial fluid pressure: A 'miniature compartment syndrome'. *Journal of Neurology, Neurosurgery, and Psychiatry*, 46, 1119–1124.
- MacDermid, J., & Wessel, J. (2004). Clinical diagnosis of carpal tunnel syndrome: A systematic review. *Journal of Hand Therapy*, 17, 309–319.
- Mackinnon, S. (1992). Double and multiple 'crush' syndromes: Double and multiple entrapment neuropathies. *Hand Clinics*, 8, 369–390.
- Mackinnon, S., Dellon, A., Hudson, A., & Hunter, D. (1984). Chronic nerve compression: An experimental model in the rat. *Annals of Plastic Surgery*, 13, 112–120.
- Magee, D. (2002). *Orthopaedic physical assessment* (4th ed.). Philadelphia, PA: Saunders.
- Main, C., & Watson, P. (1999). Psychological aspects of pain. *Manual Therapy*, 4, 203–215.
- Maitland, G. (1979). Negative disc exploration: Positive canal signs. *Australian Journal of Physiotherapy*, 25, 129–134.
- Maitland, G. (1985). The slump test: Examination and treatment. *Australian Journal of Physiotherapy*, 31, 215–219.
- Mannion, R., & Woolf, C. (2000). Pain mechanisms and management: A central perspective. *The Clinical Journal of Pain*, 16(Suppl.), S144–S156.
- McCroly, P., Bell, S., & Bradshaw, C. (2002). Nerve entrapments of the lower leg, ankle and foot in sport. *Sports Medicine*, 32, 371–391.
- Melzack, R. (1996). Gate control theory: On the evolution of pain concepts. *Pain Forum*, 5, 128–138.
- Melzack, R. (2005). Evolution of the neuromatrix theory of pain. *Pain Practice*, 5, 85–94.
- Merskey, H., & Bogduk, N. (1994). *Classification of chronic pain: Descriptions of chronic pain syndromes and definitions of pain terms* (2nd ed.). Seattle, WA: IASP Press.
- Meyer, J., Kulig, K., & Landel, R. (2002). Differential diagnosis and treatment of subcalcaneal heel pain: A case report. *Journal of Orthopaedic and Sports Physical Therapy*, 32, 114–124.
- Millesi, H., Zoch, G., & Rath, T. (1990). The gliding apparatus of peripheral nerve and its clinical significance. *Annals of Hand Surgery*, 9, 87–97.
- Millesi, H., Zoch, G., & Reihnsner, R. (1995). Mechanical properties of peripheral nerves. *Clinical Orthopaedics and Related Research*, 314, 76–83.
- Moseley, G. (2003a). A pain neuromatrix approach to patients with chronic pain. *Manual Therapy*, 8, 130–140.
- Moseley, G. (2003b). Unraveling the barriers to reconceptualization of the problem in chronic pain: The actual and perceived ability of patients and health professionals to understand the neurophysiology. *The Journal of Pain*, 4, 184–189.
- Moseley, G. (2004). Evidence for a direct relationship between cognitive and physical change during an education intervention in people with chronic low back pain. *European Journal of Pain*, 8, 39–45.
- Murata, Y., Rydevik, B., Takahashi, K., Larsson, K., & Olmarker, K. (2005). Incision of the intervertebral disc induces disintegration and increases permeability of the dorsal root ganglion capsule. *Spine*, 30, 1712–1716.
- Murphy, R. (1977). Nerve roots and spinal nerves in degenerative disk disease. *Clinical Orthopaedics and Related Research*, 129, 46–60.
- Nakamura, S., & Myers, R. (2000). Injury to dorsal root ganglia alters innervation of spinal cord dorsal horn lamina involved in nociception. *Spine*, 25, 537–542.
- Novak, C., & Mackinnon, S. (2005). Evaluation of nerve injury and nerve compression in the upper quadrant. *Journal of Hand Therapy*, 18, 230–240.
- Nuckley, D., Konodi, M., Raynak, G., Ching, R., & Mirza, S. (2002). Neural space integrity of the lower cervical spine: Effect of normal range of motion. *Spine*, 27, 587–595.
- O'Brien, J., Mackinnon, S., MacLean, A., Hudson, A., Dellon, A., & Hunter, D. (1987). A model of chronic nerve compression in the rat. *Annals of Plastic Surgery*, 19, 430–435.
- Ogata, K., & Naito, M. (1986). Blood flow of peripheral nerve effects of dissection, stretching and compression. *Journal of Hand Surgery*, 11B, 10–14.
- Olmarker, K., & Rydevik, B. (1991). Pathophysiology of sciatica. *Orthopedic Clinics of North America*, 22, 223–234.
- Pahor, S., & Toppenberg, R. (1996). An investigation of neural tissue involvement in ankle inversion sprains. *Manual Therapy*, 1, 192–197.
- Parke, W., & Whalen, J. (2002). The vascular pattern of the human dorsal root ganglion and its probable bearing on a compartment syndrome. *Spine*, 27, 347–352.
- Petty, N., & Moore, A. (2001). *Neuromusculoskeletal examination and assessment: A handbook for therapists* (2nd ed.). Edinburgh: Churchill Livingstone.
- Phillips, J., Smit, X., DeZoysa, N., Afoke, A., & Brown, R. (2004). Peripheral nerves in the rat exhibit localized heterogeneity of tensile properties during limb movement. *Journal of Physiology*, 557, 879–887.
- Rempel, D., Dahlin, L., & Lundborg, G. (1999). Pathophysiology of nerve compression syndromes: Response of peripheral nerves to loading. *Journal of Bone and Joint Surgery (Am)*, 81A, 1600–1610.
- Rozmaryn, L., Dovel, S., Rothman, E., Gorman, K., Olvey, K., & Bartko, J. (1998). Nerve and tendon gliding exercises and the conservative management of carpal tunnel syndrome. *Journal of Hand Therapy*, 11, 171–179.
- Rutkowski, M., Winkelstein, B., Hickey, W., Pahl, J., & DeLeo, J. (2002). Lumbar nerve root injury induces central nervous system neuroimmune activation and neuroinflammation in the rat: Relationship to painful radiculopathy. *Spine*, 27, 1604–1613.
- Rydevik, B., Brown, M., & Lundborg, G. (1984). Pathoanatomy and pathophysiology of nerve root compression. *Spine*, 9, 7–15.
- Rydevik, B., Myers, R., & Powell, H. (1989). Pressure increase in the dorsal root ganglion following mechanical compression: Closed compartment syndrome in nerve roots. *Spine*, 14, 574–576.
- Sauer, S., Bove, G., Averbek, B., & Reeh, P. (1999). Rat peripheral nerve components release calcitonin gene-related peptide and prostaglandin E2 in response to noxious stimuli: Evidence that nervi nervorum are nociceptors. *Neuroscience*, 92, 319–325.
- Schon, L., Glennon, T., & Baxter, D. (1993). Heel pain syndrome: Electrodiagnostic support for nerve entrapment. *Foot and Ankle*, 14, 129–135.
- Scrimshaw, S., & Maher, C. (2001). Randomized controlled trial of neural mobilization after spinal surgery. *Spine*, 26, 2647–2652.
- Shacklock, M. (1995a). Clinical applications of neurodynamics. In M. Shacklock (Ed.), *Moving in on pain* (pp. 123–131). Australia: Butterworth-Heinemann.
- Shacklock, M. (1995b). Neurodynamics. *Physiotherapy*, 81, 9–16.
- Shacklock, M. (1999). Central pain mechanisms: A new horizon in manual therapy. *Australian Journal of Physiotherapy*, 45, 83–92.
- Shacklock, M. (2005). *Clinical neurodynamics: A new system of musculoskeletal treatment*. Edinburgh: Elsevier/Butterworth Heinemann.
- Slipman, C., Plastaras, C., Palmitier, R., Huston, C., & Sterenfeld, E. (1998). Symptom provocation of fluoroscopically guided cervical nerve root stimulation: Are dynamical maps identical to dermatomal maps? *Spine*, 23, 2235–2242.
- Sterling, M., Treleaven, J., & Jull, G. (2002). Responses to a clinical test of mechanical provocation of nerve tissue in whiplash associated disorder. *Manual Therapy*, 7, 89–94.
- Sunderland, S. (1990). The anatomy and physiology of nerve injury. *Muscle and Nerve*, 13, 771–784.

- Sunderland, S. (1991). *Nerve injuries and their repair: A critical appraisal*. Edinburgh: Churchill Livingstone.
- Takahashi, N., Yabuki, S., Aoki, Y., & Kikuchi, S. (2003). Pathomechanisms of nerve root injury caused by disc herniation: An experimental study of mechanical compression and chemical irritation. *Spine*, 28, 435–441.
- Takebayashi, T., Cavanaugh, J., Ozaktay, A., Kallakuri, S., & Chen, C. (2001). Effect of nucleus pulposus on the neural activity of dorsal root ganglion. *Spine*, 26, 940–945.
- Tal-Akabi, A., & Rushton, A. (2000). An investigation to compare the effectiveness of carpal bone mobilisation and neurodynamic mobilisation as methods of treatment for carpal tunnel syndrome. *Manual Therapy*, 5, 214–222.
- Tanaka, N., Yoshinori, F., An, H., Ikuta, Y., & Yasuda, M. (2000). The anatomic relation among the nerve roots, intervertebral foramina, and intervertebral discs of the cervical spine. *Spine*, 25, 286–291.
- Triano, J., & Luttgies, M. (1982). Nerve irritation: A possible model of sciatic neuritis. *Spine*, 7, 129–136.
- van der Heide, B., Allison, G., & Zusman, M. (2001). Pain and muscular responses to a neural tissue provocation test in the upper limb. *Manual Therapy*, 6, 154–162.
- Vicenzino, B., Collins, D., & Wright, A. (1996). The initial effects of a cervical spine manipulative physiotherapy treatment on the pain and dysfunction of lateral epicondylalgia. *Pain*, 68, 69–74.
- Vicenzino, B., Neal, R., Collins, D., & Wright, A. (1999). The displacement, velocity and frequency profile of the frontal plane motion produced by the cervical lateral glide treatment technique. *Clinical Biomechanics*, 14, 515–521.
- Vlaeyen, J., & Linton, S. (2000). Fear-avoidance and its consequences in chronic musculoskeletal pain: A state of the art. *Pain*, 85, 317–332.
- Vogt, B. (2005). Pain and emotion interactions in subregions of the cingulate gyrus. *Nature Reviews: Neuroscience*, 6, 533–544.
- Wainner, R., Fritz, J., Irrgang, J., Boninger, M., Delitto, A., & Allison, S. (2003). Reliability and diagnostic accuracy of the clinical examination and patient self-report measures for cervical radiculopathy. *Spine*, 28, 52–62.
- Wainner, R., Fritz, J., Irrgang, J., Delitto, A., Allison, S., & Boninger, M. (2005). Development of a clinical prediction rule for the diagnosis of carpal tunnel syndrome. *Archives of Physical Medicine and Rehabilitation*, 86, 609–618.
- Wall, P. (1991). Neuropathic pain and injured nerve: Central mechanisms. *British Medical Bulletin*, 47, 631–643.
- Watkins, L., & Maier, S. (2004). Neuropathic pain: The immune connection. *Pain Clinical Updates*, 13, 1–4.
- White, D. (1997). Release of substance P from peripheral sensory nerve terminals. *Journal of the Peripheral Nervous System*, 2, 191–201.
- Woolf, C. (2004). Dissecting out mechanisms responsible for peripheral neuropathic pain: Implications for diagnosis and therapy. *Life Sciences*, 74, 2605–2610.
- Woolf, C., & Mannion, R. (1999). Neuropathic pain: Aetiology, symptoms, mechanisms, and management. *Lancet*, 353(June 5), 1959–1964.
- Yabuki, S., Onda, A., Kikuchi, S., & Myers, R. (2001). Prevention of compartment syndrome in dorsal root ganglia caused by exposure to nucleus pulposus. *Spine*, 26, 870–875.
- Yaxley, G., & Jull, G. (1993). Adverse tension in the neural system: A preliminary study of tennis elbow. *Australian Journal of Physiotherapy*, 39, 15–22.
- Zochodne, D. (1993). Epineural peptides: A role in neuropathic pain? *Canadian Journal of Neurological Sciences*, 29, 69–72.
- Zusman, M. (1992). Central nervous system contribution to mechanically produced motor and sensory responses. *Australian Journal of Physiotherapy*, 38, 195–202.
- Zusman, M. (2002). Forebrain-mediated sensitization of central pain pathways: ‘Non-specific’ pain and a new image for MT. *Manual Therapy*, 7, 80–88.